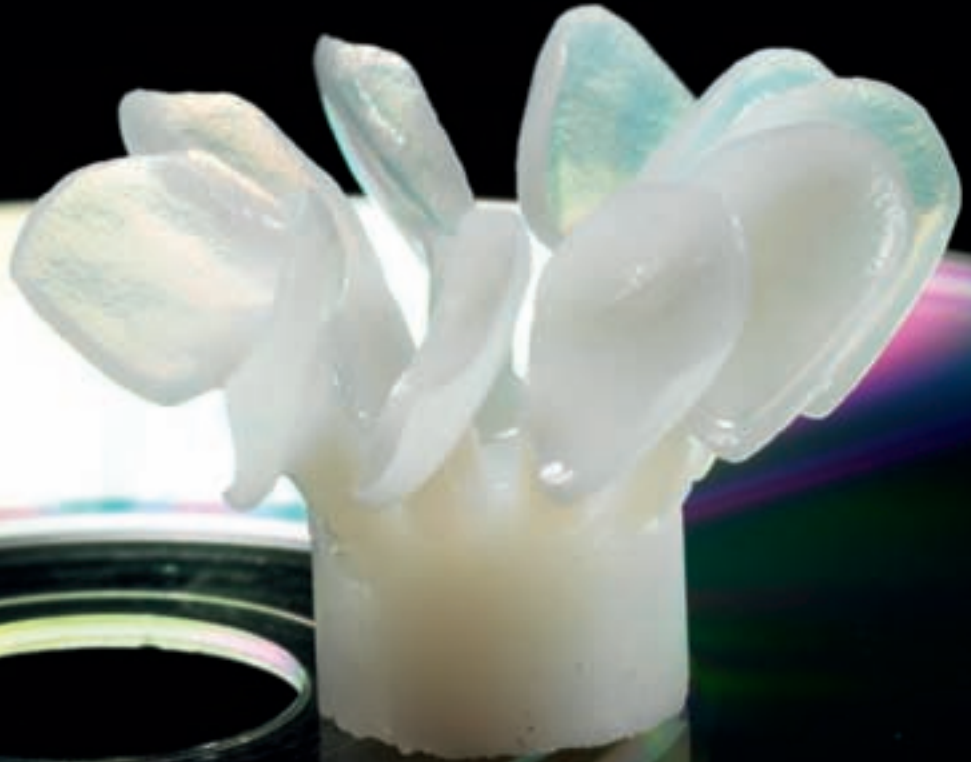

REFLECT

d e n t a l p e o p l e f o r d e n t a l p e o p l e 0 1 / 1 1



On target with more brightness

Creating esthetic veneers with IPS e.max® Press

A lasting bond

Implant-borne single-tooth restorations using IPS e.max® CAD-on

Composite resin – the material of choice

Reconstruction of anterior dentition with IPS Empress® Direct

Editorial

Dear Reader



Recently I spent an evening touring the spectacular Sydney Harbour with a group of dentists and dental technicians. As we admired the beautiful Sydney Opera House a dentist who lives in Sydney explained the background of the innovative architecture and the world attention that the design

has attracted. Several of us have been in dentistry for many years and the conversation predictably moved to dentistry. The focus was on innovation and the innovative process. One particular question resulted in a lot of comments and extensive discussion. Specifically, I was asked how dental companies and especially our dental company create "innovations". It was a good question and the conversation that followed was interesting enough that I would like to share it with you.

I explained that there is a scientific definition of innovation and a practical definition of innovation. You need to know and understand the definitions to appreciate the value of the question. First, let's look at the scientific definition. From a scientific direction innovation means to create something new. It could be a new formula or a new process but it must be new. This definition emanates from the direction of the manufacturer. Typically, this is a new science. The practical definition starts most often with the user of the product and not the manufacturer. They see innovation as something that improves a situation or solves a problem. Now the question becomes, "Is innovation a science or a solution?" This is the real question because it goes directly to the topic of the innovation's value. It is also the true question at the basis of our Sydney Harbour conversation. I told one of the den-

tists that I was asking him questions earlier in the evening about products and his practice to try to understand his challenges. I wanted to understand the problems so that I could direct the focus of our R&D teams in the direction of the need. He then asked if I was part of the R&D team. I answered, "Yes, and in a way so are you."

The explanation of the innovative process was and is generally simple. In our company and in other companies most science is directed toward customer needs. You determine the customer needs by asking questions and listening. This process is a type of bridge-building. You build a bridge from the customer to the manufacturer. It is a bridge from the customer need to the development process. This Innovation Bridge assists the science to reach the solution. When the architect of the Sydney Opera House first met with the Sydney Officials most likely he asked them what their needs and wants for the new building were. Also, a dental company needs to know what you want and what you need. The communication is formal and informal but it must exist or the science is just science.

This is the innovation process and this is how it is done at Ivoclar Vivadent and at other companies. It is as much about communication as it is about chemistry. We try to be good listeners. We strive to develop products according to customer needs. Our goal is to bring innovation that creates opportunities for the dental technician, the dentist and the patient. Simply stated, we try to be good listeners and then good innovators.

Sincerely

A handwritten signature in black ink, appearing to read "Robert A. Ganley". The signature is fluid and cursive.

Robert A Ganley
CEO Ivoclar Vivadent

The cover picture shows IPS e.max® Press Impulse veneers after divesting (photo: Nicole Schweizer).

Editorial

The value of innovation 02
Robert A Ganley (USA)

Dental medicine

Composite resin – the material of choice 04
Dr Gabriel Krastl (CH)

Generation fifty plus: Restoring a natural smile 08
*Dr Giovanni Molina Lugo, Dr Francisco Paul Curiel
 Aguilera and Dr Carlos A Ramirez Schleske (MX)*

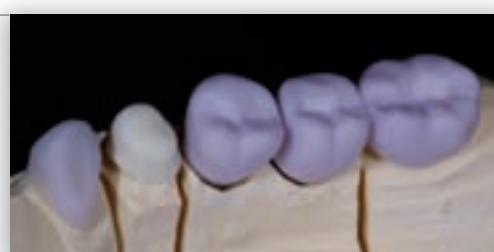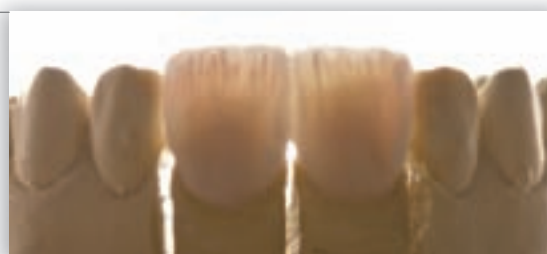
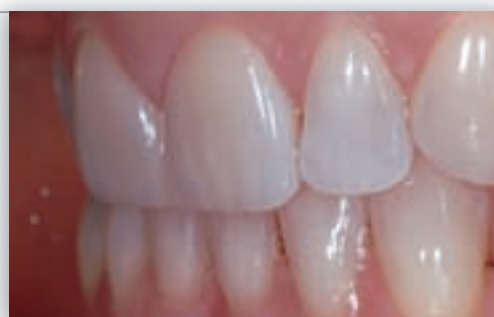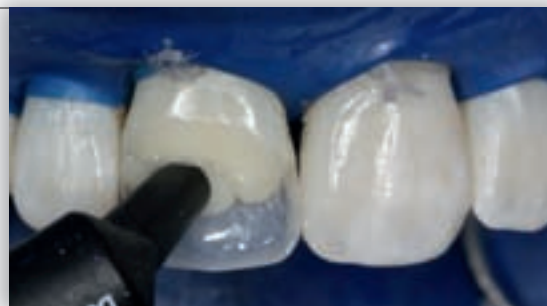Teamwork

On smile design 12
*Dr Stephen Phelan (CA)
 and Harald Heindl, MDT (USA)*

Dental technology

On target with more brightness 16
Benjamin Votteler, MDT (D)

A lasting bond 20
*Oliver Morhofer, MDT,
 and Bernd Kobus, MDT (D)*

**PUBLISHER'S CORNER**

Publisher	Ivoclar Vivadent AG Bendererstr 2 9494 Schaan / Liechtenstein Tel +423 / 235 35 35 Fax +423 / 235 33 60	Coordination	Lorenzo Rigliaco Tel +423 / 235 36 98
Publication	3 times a year	Editorial office	Dr R May, N van Oers, L Rigliaco, T Schaffner
Total circulation	70,200 (Languages: German, English, French, Italian, Spanish, Russian)	Reader service	info@ivoclarvivadent.com
		Production	teamwork media GmbH, Fuchstal/Germany

Composite resin – the material of choice

Reconstruction of anterior dentition with IPS Empress® Direct

Dr Gabriel Krastl, Basel/Switzerland

Re-creating the original tooth as faithfully as possible is a challenging task for both the operator and the dental material. However, modern materials and layering schemes modeled on the natural structure of the tooth provide a sound basis on which predictable esthetic results can be achieved. The present case study describes the restoration of a fractured anterior tooth and discusses the biomimetic properties of IPS Empress Direct.

The young female patient was dissatisfied with the appearance of her upper teeth, which resulted from an accident a few years previously in which tooth 11 was injured. Therefore, she wished to have corrective work done. After the dental trauma, the tooth was restored with composite resin.

The clinical examination showed that the teeth were free of caries and in overall good condition in accordance with the patient's age. The patient clearly practiced excellent oral hygiene (Fig 1). Compared with the adjacent teeth, the natural part of tooth 11 looked yellowish and the composite build-up appeared greyish

and translucent. With the exception of tooth 11, all the teeth reacted to the sensitivity test. The probing depth of the gingival sulcus measured less than three millimetres. Tooth 11 showed minimal percussion sensitivity. The periapical X-ray revealed traces of an apical lesion (Fig 2). The root canal seemed to be extensively calcified.

As discussed with the patient, root canal treatment was planned for tooth 11. Furthermore, subsequent internal bleaching of the tooth was proposed, in preparation for the new composite build-up.

Root canal treatment

The oral cavity was isolated with a rubber dam before the root canal was opened. The canal was difficult to locate, despite the use of an operating microscope. Nevertheless, it was found at a depth of 13 millimetres. The root canal was prepared and a calcium hydroxide medicated filling placed for two weeks. Subsequently, the root canal was filled with thermoplastic gutta-percha points and sealed. The cervical structure of tooth 11 was internally bleached with sodium perborate until the tooth structure acquired the shade of the adjacent tooth.

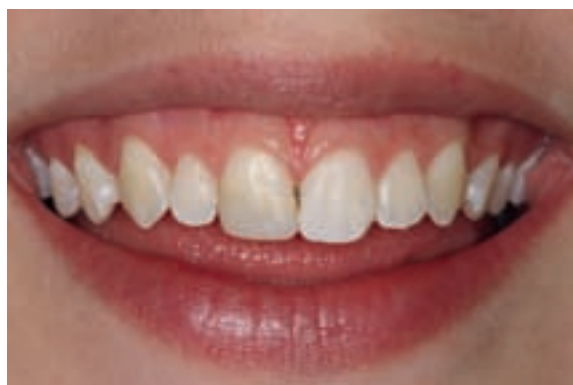

Fig 1 The preoperative situation shows that tooth 11 has been restored rather unattractively.

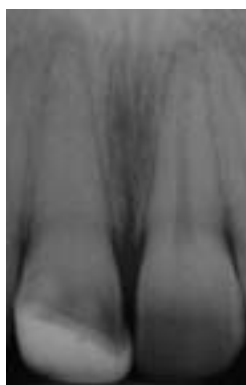

Fig 2 X-ray showing apical periodontitis in tooth 11

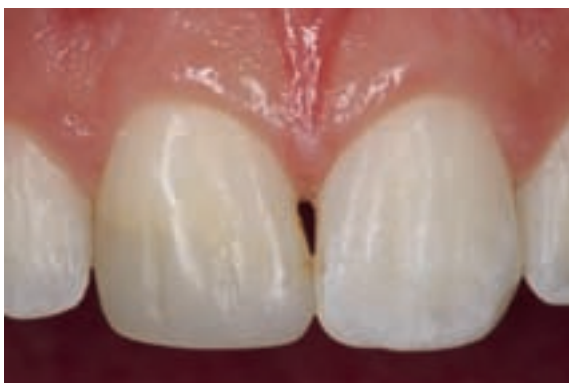

Fig 3 Close-up of teeth 11 and 21

Analysis of the tooth shape and shade

A close look at the two central incisors showed that the teeth were slightly asymmetrical (Fig 3), that is, the crown of tooth 11 looked somewhat wider. When the patient was questioned about this finding, she confirmed that she had had a median diastema, which was closed when the restorative work was done after her accident.

The appropriate enamel and dentin materials were selected with the shade guide from the IPS Empress Direct Set. The dentin materials were matched to the cervical area of the tooth and the enamel material was selected in accordance with the incisal area of the adjacent teeth.

The build-up of a tooth is a very sophisticated procedure, which needs to be planned very carefully. In order to ascertain and visualize the desired result before the tooth is built up, it is useful to draw up a "map" of the tooth's characteristics. For example, this "map" will show the areas that are highly translucent or opaque. Furthermore, a photo of the preoperative situation, which can be viewed on the display of a digital camera as necessary, could be of invaluable use in the subsequent build-up procedure. Nevertheless, it is important to note that digital photos only provide a rough indication regarding the placement of the different composite resins and staining materials. Photographs do not convey true colour. In the present case, the following materials were used for building up the composite resin restorations: A3 Dentin, A2 Enamel, Trans Opal and Tetric® Color white.

Mock-up and silicone matrix

A mock-up was prepared for the purpose of fabricating a silicone matrix. The shape and contour of the existing restoration were congruent with the neighbouring tooth 12 to a large extent. Therefore, only small adjustments of shape were necessary. For example, the incisal edge was slightly lengthened in the distal region. Silicone putty was used to record the information provided by the mock-up. Since only the palatal part and the

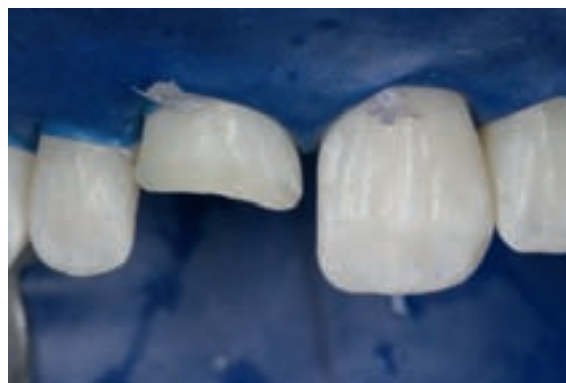

Fig 4 The old filling has been removed and tooth 11 has been prepared.

incisal edge of the silicone matrix were needed for building up tooth 11, the matrix was correspondingly trimmed with a scalpel.

Preparation, adhesive pretreatment and adjustments to the adjacent tooth

The old composite resin restoration was removed with rotating instruments. Furthermore, the enamel margins were beveled. A wide area was prepared in the labial region in particular (approx 2 mm) to ensure the invisibility of the final restoration margin (Fig 4). A rubber dam was placed in the anterior teeth (up to the first premolar) to establish a full view of the treatment field. Ligatures helped to completely isolate the anterior teeth requiring treatment and to displace the rubber dam towards the gingival margin. A three-step system including phosphoric acid etching (eg Syntac® Classic) was used for the adhesive pretreatment of the tooth structure. In order to make the two anterior teeth look symmetrical and to close the diastema, the mesial region of tooth 21 had to be widened a little with enamel material.

Build-up of palatal and proximal surfaces

The main aim of the anatomic layering technique is to create an artificial "enamel shell", which establishes the palatal and proximal contour of the original tooth. In the present case, a small amount of transparent enamel material (A2 Enamel) was placed in the trimmed silicone matrix and distributed to a thin layer with a spatula. The defect had to be covered as completely as possible. Some flowable Tetric EvoFlow® was applied to the palatal defect margin of the prepared tooth 11. Next, the silicone matrix together with the enamel materials was placed on the anterior teeth from the palatal aspect and checked for correct fit. If the enamel material in the silicone matrix has been properly placed, it will reach the cervical margin of the defect. The flowable material on the tooth is thus displaced and fills out possible voids. Furthermore, it ensures good marginal adaptation.

The restoration was initially polymerized from the labial aspect. Next, the silicone matrix was carefully

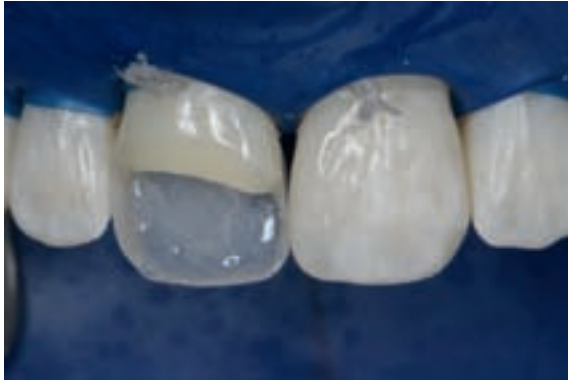

Fig 5 After the adhesive pretreatment the palatal “enamel shell” is created.

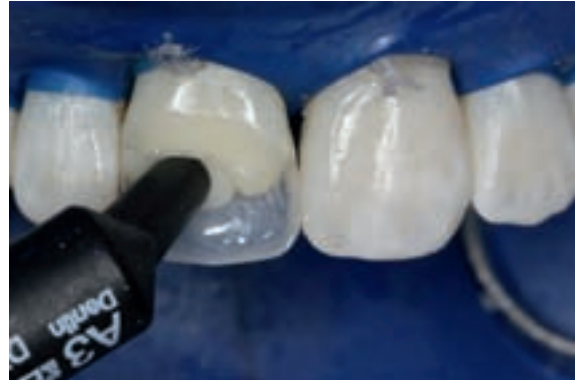

Fig 6 The dentin core is deliberately built up generously.

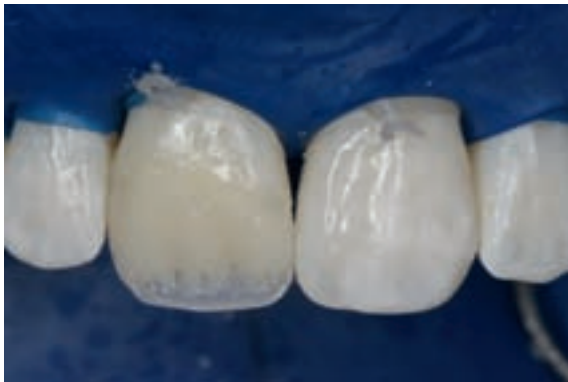

Fig 7 The built up dentin core provides only very little space for the enamel material.

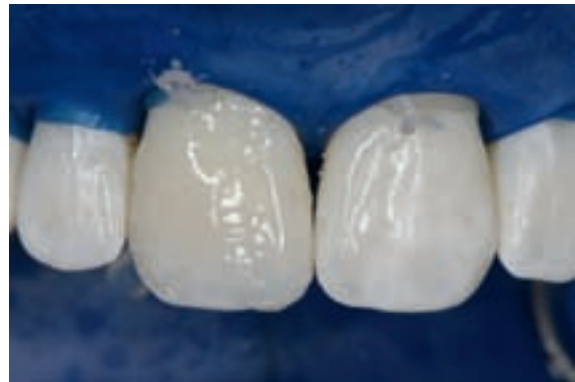

Fig 8 The restoration is ready for polishing after it has been characterized with translucent and white-opaque materials and sculpted.

removed and the built up composite resin was polymerized from the palatal aspect. Small amounts of excess in the palatal and proximal areas were easy to remove with a scalpel (Size 12). The palatal surface prepared in this way produced the desired width in the incisal area. Nevertheless, the proximal part of the restoration did not make contact with the neighbouring tooth at this stage. The chosen matrix technique has a decisive influence on the creation of the most natural-looking proximal contours possible. As the mesial and distal portions of the defect were located supergingivally in the present case, transparent matrices were used, which were held in place with wooden wedges. The proximal wall was built up with utmost precision. After the matrix and wedges were removed, the thin composite layer significantly enhanced the appearance of the incisal, palatal and proximal contours of the tooth (Fig 5).

Build-up of the dentin core

The subsequent layers were placed with opaque dentin material (IPS Empress® Direct Dentin, A3). The dentin core was built up (Fig 6). In comparison with natural teeth, this part of the tooth was larger. As a result, the space available for the enamel coating was very limit-

ed. It seemed to make good sense to cover the enamel bevel with dentin material as well.

This measure prevents the restoration margin from becoming visible as a grey line. Towards the incisal part the dimensions and the morphology of the dentin core were determined by the neighbouring and contralateral teeth. In the present case, mamelon structures were created. In the incisal area, enough space was provided for the translucent enamel materials (Fig 7). Each increment was cured for 20 seconds using a bluephase® LED light.

Incisal characterization

The incisal part between the mamelons was filled with a special composite resin material (IPS Empress® Direct Opal). A natural opalescent appearance was simulated with this technique. In addition, a white staining material (Tetric Color white) was selectively applied in order to re-create the whitish opaque areas of the enamel.

Build-up of the labial areas

The restoration was completed by applying a last thin enamel layer (IPS Empress® Direct Enamel A2) on the labial side (Fig 8).

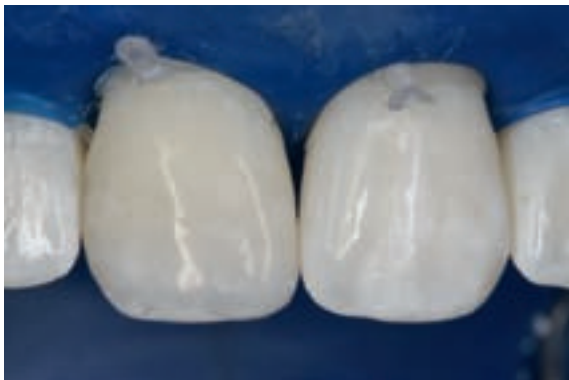

Fig 9 After polishing: A natural-looking surface lustre and a fine morphological structure was produced with the suitable polishing technique.

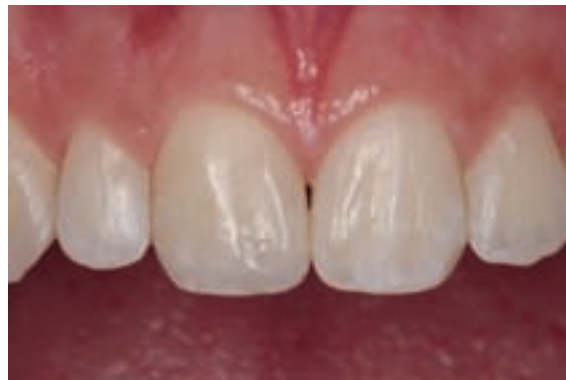

Fig 10 Four weeks later, the follow-up examination showed a normal clinical situation.

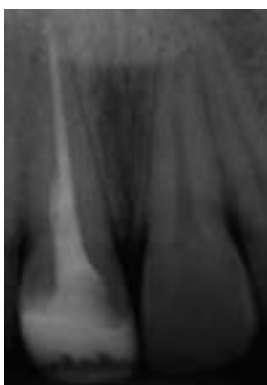

Fig 11
The final X-ray showing the root canal filling and composite restoration

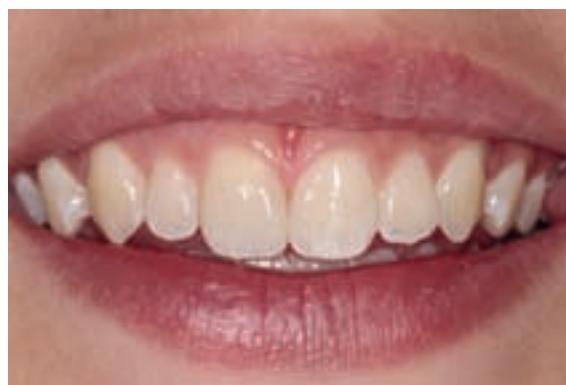

Fig 12 The smile of a satisfied patient

While the resin composite was still soft, the surface texture of the restoration was created with a brush. The tooth shape was modeled in a way that would reduce the subsequent finishing work to a minimum.

Finishing and polishing

Excess material was removed with a scalpel (Size 12). Suitable finishers and polishers were used to adjust the surface gloss and micro-morphology of the tooth to that of the adjacent teeth. Restorative margins were finished and adjustments of the proximal and incisal areas were made with flexible discs. In labial areas, these instruments must be used with great care to prevent the destruction of the morphology and the accidental removal of enamel material. Concave areas in the buccal surface were deepened in places with silicone polishers. High-gloss polishing was done with silicon-carbide impregnated brushes (Astrobrush®) (Fig 9).

Recall

Four weeks after the treatment ended, the clinical situation looked healthy. The restoration in tooth 11 was virtually invisible. Symmetry has been restored to the anterior dentition (Fig 10). In addition, the radio-

logical follow-up exam did not show any irregularities (Fig 11). The patient was free from any complaints and highly satisfied with the overall result (Fig 12). □

Contact details:

Dr Gabriel Krastl
Leiter Zahnunfallzentrum Basel
Klinik für Parodontologie, Endodontologie und Kariologie
Universitätskliniken für Zahnmedizin der Universität Basel
Hebelstrasse 3
4056 Basel
Switzerland
gabriel.krastl@unibas.ch





Generation fifty plus: Restoring a natural smile

The fabrication of esthetic, implant-supported complete dentures with the BPS® System

Dr Giovanni Molina Lugo, Colonia Polanco, Dr Francisco Paul Curiel Aguilera, San Francisco del Rincón, and Dr Carlos A Ramirez Schleske, Granada/all from Mexico

Today's quality conscious and vital seniors wish to retain an attractive appearance in the later stages of their life. They demand removable dentures that allow them to lead active lives and enjoy life to the full. Consequently, esthetics are an important issue. Clinicians seeking to fulfil the demands of today's seniors require well-thought-out strategies and materials that feature appropriate properties. In this article, the authors provide insight into the Biofunctional Prosthetic System (BPS), a high-quality denture system which satisfies the needs of discerning patients.

In the past decades, the Biofunctional Prosthetic System has established itself as the standard of care in complete denture prosthetics. The success of the system lies in the interplay of coordinated products, their correct use on the patient and the effective collaboration between dentist and dental technician. Among other things, the system comprises a range of tools (eg articulators) to re-establish efficient chewing function as well as optimally coordinated materials (eg denture base resins) which allow the soft tissues to be reproduced and denture teeth and metal frameworks to be joined. The BPS system comprises all the components required for the clinical and laboratory procedures involved in the fabrication of dentures. Consequently, a smooth flow of communication between the different parties – patient, dentist and dental technician – is ensured.

The increasing demand for implant-supported dentures is easily explained by the fact that today's patients stay active and in good health even at an advanced age. They want to enjoy life to the full. In this context, implant-supported dentures may contribute substantially to enhancing their quality of life. One of the main

benefits of the BPS system is that it offers all the components required from the planning of a case to its completion, thus allowing successful results to be achieved. The launch of a new generation of denture teeth – SR Phonares® NHC – has further increased the level of quality achievable in the fabrication of esthetic dentures for the edentulous patient. Due to innovative features such as wear resistance, low plaque accumulation, low tendency to discoloration as well as natural shape and shade, these new denture teeth are the first choice for high-quality prosthetic solutions.

Diagnosis and treatment planning

A 57-year-old female patient presented to our dental practice. She was unhappy with the esthetic appearance of her dentures as well as their masticatory function. A careful clinical and radiological examination, which was followed by an analysis of the diagnostic casts in the articulator, revealed generalized, complex, chronic periodontal disease with poor prognosis, which affected the entire remaining dentition (Figs 1 and 2). After having discussed the different treatment options with the patient, the following treatment plan was set up:

- ❑ Extraction of the residual teeth not worth preserving and fabrication of provisional dentures;
- ❑ Insertion of five implants in the maxilla and five implants in the mandibula;
- ❑ Rehabilitation by means of fixed, implant-supported upper and lower dentures.

Provisional dentures

As a first working step, immediate dentures were fabricated with the BPS system (Fig 3). At the same time, multiple extractions were done and the alveolar ridge

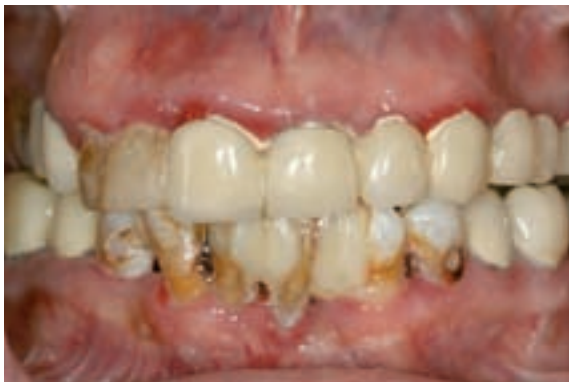

Fig 1 Starting situation: The remaining teeth were found to be affected by periodontal disease.

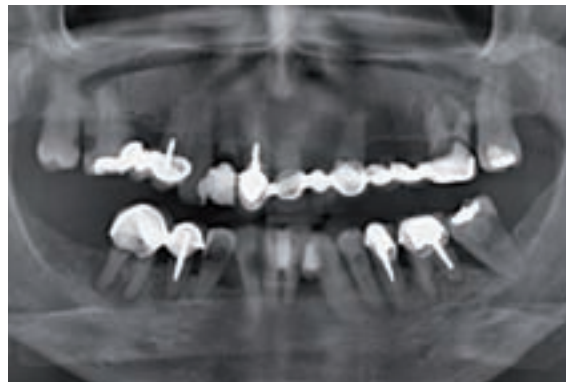

Fig 2 The X-ray revealed loosening of the remaining natural dentition as well as defective restorations.

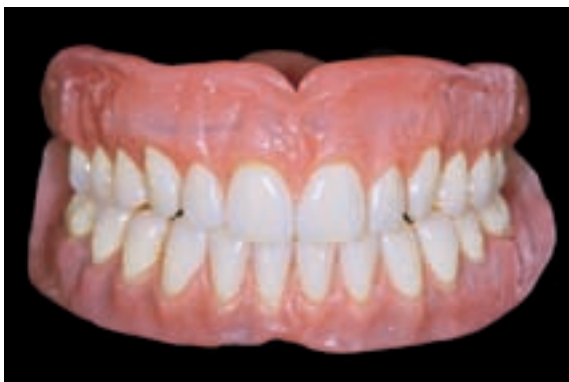

Fig 3 Following extraction of the remaining teeth, the immediate dentures (fabricated with the BPS system) were incorporated.

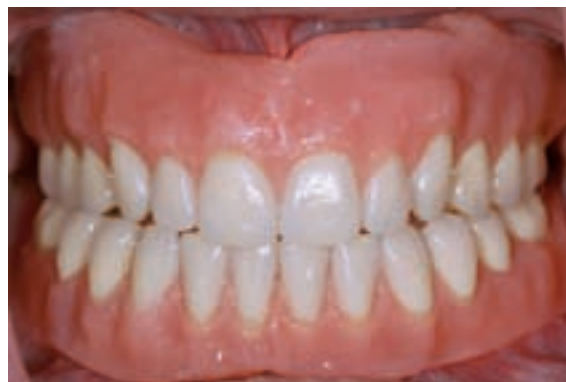

Fig 4 The provisional dentures in situ. Bone re-modelling took place in the course of the three-month healing period.

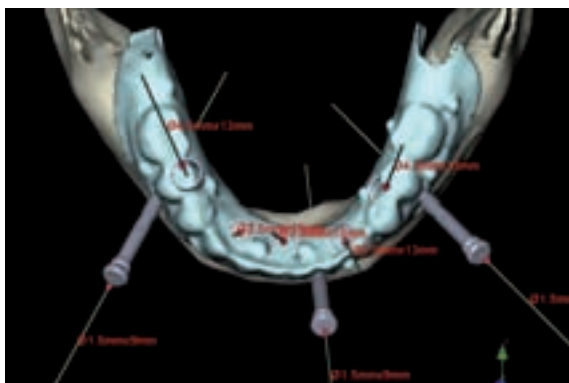


Fig 5 Planning of the surgical intervention. The superposed image of the immediate denture formed the basis for the correct placement of the implants.

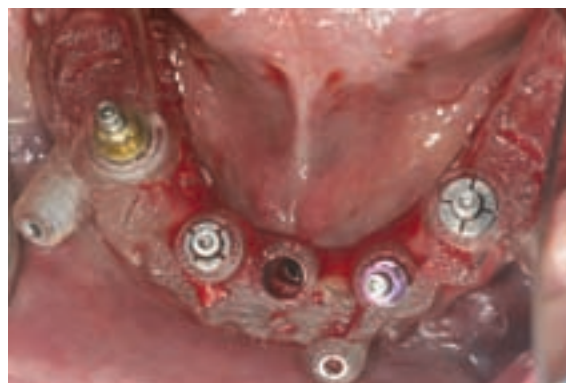

Fig 6 The implant bed was prepared using a drilling template and the implants were inserted.

was adjusted where necessary. The patient left our surgery with the provisional dentures in place. These remained in the mouth during the healing period of three months (Fig 4).

BPS as a planning tool in computer-assisted oral surgery

A cone beam CT scan was carried out. Based on this scan, the surgical intervention required to place the im-

plants was planned using digital 3-D implant planning software. The interim dentures served as a reference in this process. This helped to ensure the correct positioning and insertion angle of the implant fixtures in relation to the planned prosthetic superstructure (Fig 5). Surgical templates for implant bed preparation were fabricated using stereolithography. They made the procedure less traumatic for the patient and ensured high precision (Fig 6).

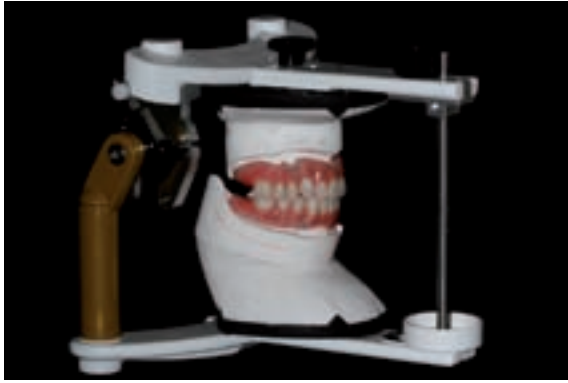

Fig 7 Set-up of the denture teeth in the articulator (Stratos 300)

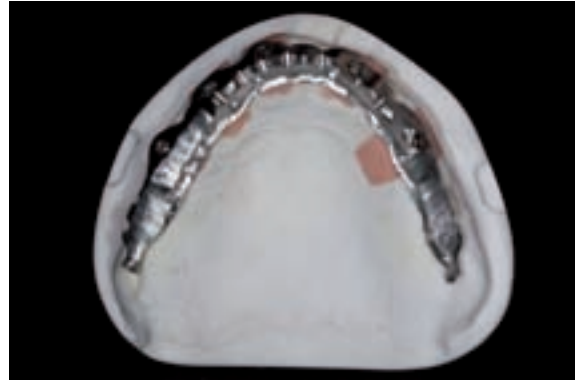

Fig 8 CAD/CAM-fabricated titanium framework for the upper jaw

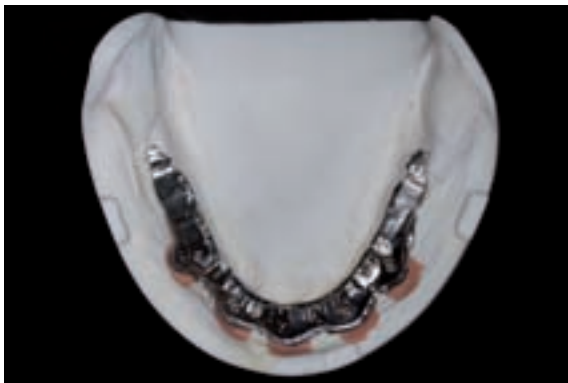

Fig 9 CAD/CAM-fabricated titanium framework for the lower jaw

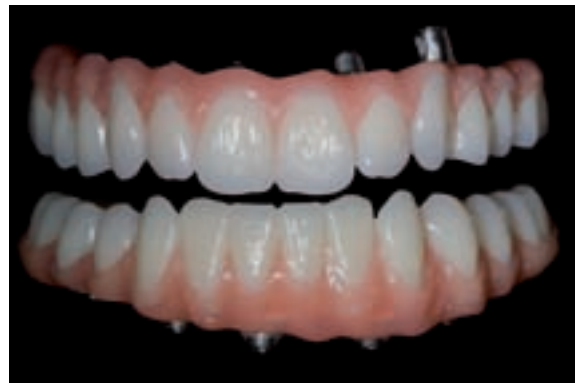

Fig 10 The completed dentures ready for final incorporation in the mouth

Fabrication of the dentures

The fabrication of the definitive dentures involved the following steps:

1. Development of efficient chewing function

For the new dentures of the patient, SR Phonares NHC denture teeth were used. The teeth were set up according to the BPS Phonares set-up method using the articulator Stratos® 300 in conjunction with the corresponding accessories. The patient's individual data were recorded and transferred to the model using the UTS transferbow system (Fig 7).

2. Fabrication of the titanium framework

In line with the arrangement of the teeth, a titanium framework was produced using CAD/CAM technology. We decided to use titanium for the framework because this material combines biocompatibility and passivity with precision, high fracture strength and low weight (Figs 8 and 9).

3. Completion of the definitive dentures

The teeth set up in dynamic occlusion and the titanium structure were joined by means of a denture base system (SR Ivocap® Sytem). The SR Ivocap HI (High Impact) material is processed through injection moulding. It provides high impact resistance and pro-

duces no increase in vertical dimension. As a result, high accuracy of fit is ensured. A reliable bond between the denture base, the teeth and the metal framework can be achieved. Furthermore, an esthetic transition between the teeth and the adjacent soft tissue portions is created (Fig 10).

4. Incorporation of the completed dentures

The completed dentures were attached by screwing them to the implants. The screw holes were first covered with Teflon tape and then sealed with a temporary filling material (Systemp®.inlay). For the occlusal surface of the teeth, IPS Empress® Direct was used, while in soft tissue areas SR Adoro® Gingiva 4 was applied. Outstanding precision was achieved with the procedure described above, particularly as far as vertical dimension and centric occlusion were concerned (Fig 11). The seamless integration of the SR Phonares NHC denture teeth into the natural environment as well as their excellent function clearly sets them apart from earlier generations of resin teeth. These highly esthetic teeth, in combination with the technical, manual and teamwork skills of the clinician and laboratory technician, ensure a successful outcome in the prosthetic rehabilitation of the edentulous patient with implant-supported dentures (Figs 12 and 13).

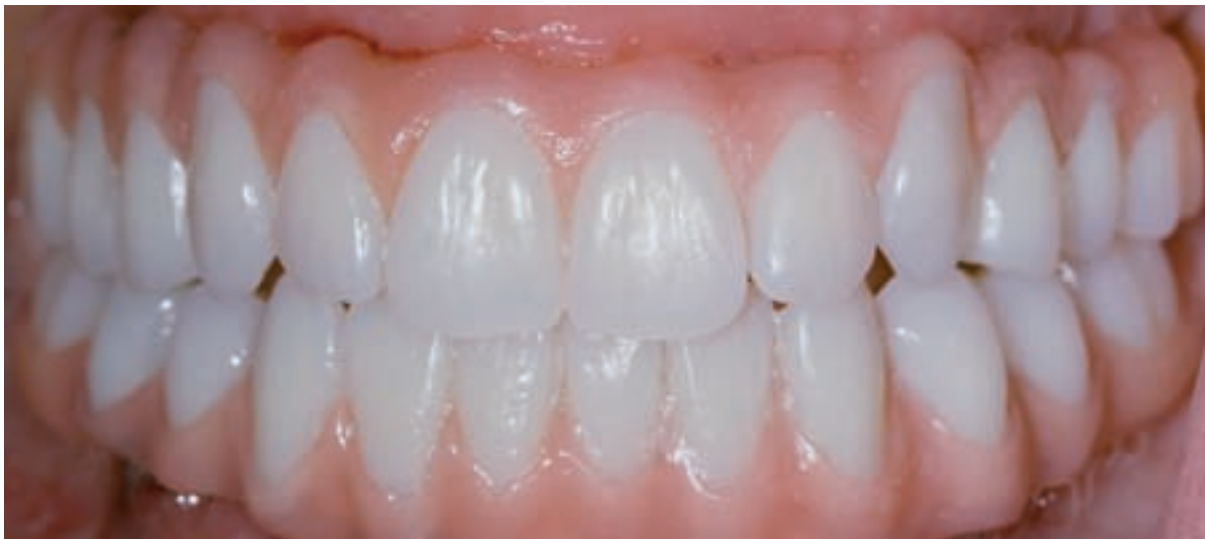

Fig 11 The denture attached to the implants with screws in the mouth of the patient

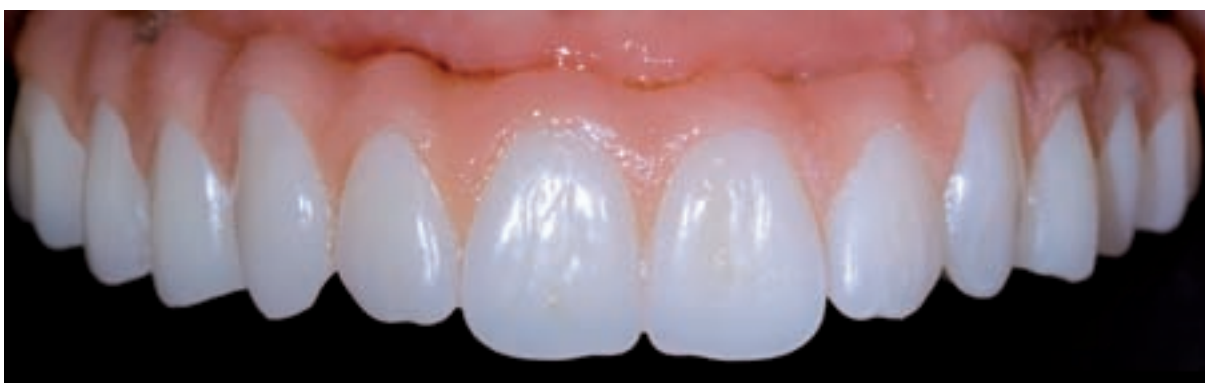

Fig 12 Excellent esthetic integration of the denture teeth (SR Phonares NHC) as well as of the soft tissue portions into the natural environment



Fig 13 A picture speaks volumes: The patient with her new, implant-supported dentures.

Conclusions

The BPS procedure described above allows complete dentures to be fabricated that provide masticatory efficiency, as well as a high level of comfort and esthetic integration. As a consequence, this type of treatment considerably enhances the patient's quality of life. The advantages for the clinician providing this type of service are obvious: The standardized, reliable system allows high-quality restorations to be fabricated in a simple, quick and cost-efficient manner – even in highly complex cases. □

Contact details:



Dr Giovanni Molina Lugo
Homero 655 PB – A01
Colonia Polanco, D.F. C.P. 11550
Mexico
begol@prodigy.net.mx



Dr Francisco Paul Curiel Aguilera
Prol. Josefa Ortiz de Domínguez #408,
Zona Centro
San Francisco del Rincón, Gto. C.P. 36300
Mexico
pacocuriel@prodigy.net.mx



Dr Carlos A Ramírez Schleske
Hospital Español Sala 4 Consultorio 7
Ave. Ejercito Nal 613 004
11520 Granada
Mexico
carsch54@prodigy.net.mx

On smile design

Conservatively placed IPS d.SIGN® veneers to correct a diastema

Dr Stephen Phelan, Oakville, Ontario/Canada, and Harald Heindl, MDT, Mill Creek, WA/USA

Today's patients expect restorations that not only function properly, but are also highly esthetic. Unlike some years ago, different media outlets today afford patients greater knowledge and insight into the possibilities and the potential of modern materials and treatment. They expect us to achieve optimum outcomes when designing their smile, and rightly so. The most significant goal, however, still is the restoration of oral health in the most conservative way.

When choosing a treatment option, dentists and technicians must satisfy not only the clinical requirements, but also the expectations and goals of the patients. In cases when patients decline orthodontic treatment, adhesively bonded porcelain veneers are a viable treatment option to modify the appearance of tooth position and form, to close diastemas or cervical embrasures or to change the tooth shade. Porcelain veneers are one of the best restorative treatment options available from biological, functional, mechanical and esthetic perspectives. Preservation of enamel is one of the main concerns if such a treatment is envisaged.

The conventional laminate veneer techniques often require aggressive removal of dental tissue, which goes against the principles of conservative dentistry. New techniques and materials allow esthetically pleasing and functionally long-lasting restorations to be produced while limiting tooth preparation. By using diagnostic guides, such as a wax-up, and a fluorapatite glass-ceramic material (IPS d.SIGN), dentists and dental technicians can fabricate minimally invasive ceramic veneers and thus provide their patients with lifelike, esthetic restorations which also meet the functional criteria.

Case presentation

A 52-year-old woman presented with complaints about the shape and size of her maxillary centrals, and she wanted the midline diastema closed (Fig 1). After discussion with the patient, it was decided that porcelain veneers (IPS d.SIGN) would be placed on teeth 11 and 21. We wanted to apply a conservative protocol to fulfil the patient's wishes.

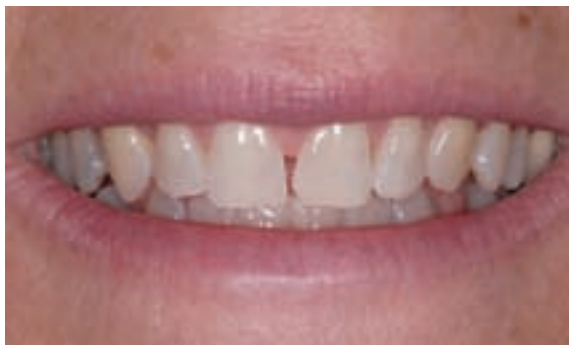

Fig 1 Initial situation: What some people see as a sign of beauty, others may see as a flaw; the patient disliked her diastema between teeth 11 and 21.

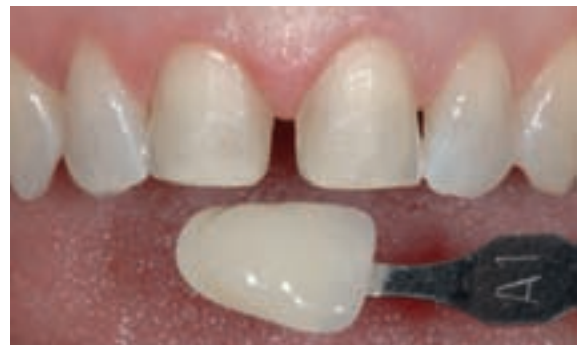

Fig 2 After conservative preparation, the shade was determined (A1).

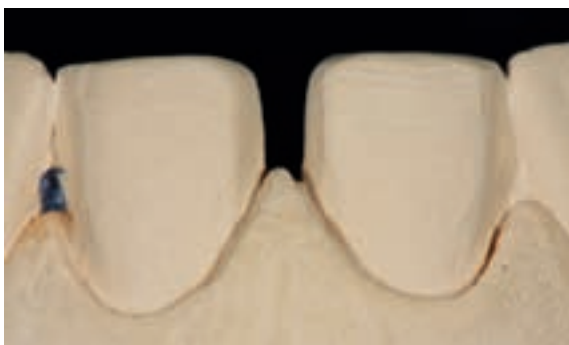

Fig 3 The working stone model for the creation of the veneers

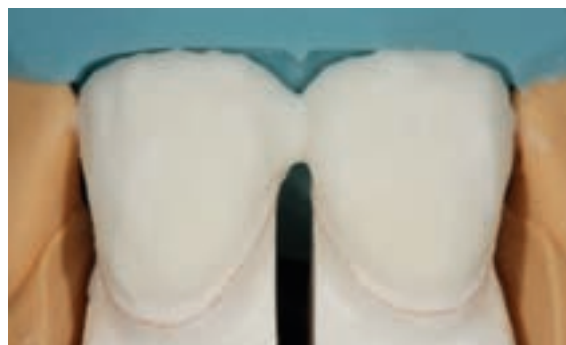


Fig 4 The material was layered on refractory dies. The silicone matrix fabricated on the basis of the wax-up was used as a guide.

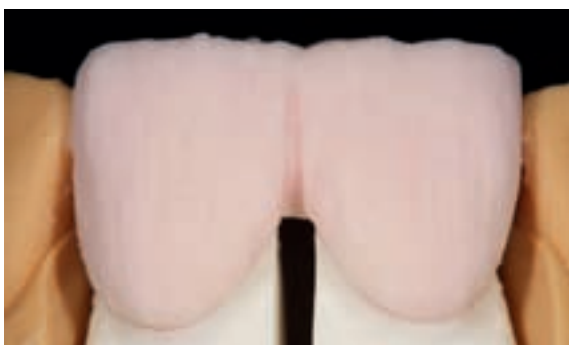

Fig 5 Quality dentin materials together with excellent technical and manual skills are required to create tooth-like veneers made up of many individual layers.

Leucite-reinforced fluorapatite layering ceramic (IPS d.SIGN, for instance) is ideal for bonded ceramic restorations such as veneers. The material's special qualities include outstanding optical properties and wear behaviour. The physical properties are very close to those found in natural teeth. As a result, IPS d.SIGN is the material of choice for treatments requiring conservative veneers.

By using a direct layering technique on refractory dies, laboratory ceramists can provide their customers and patients with restorations which display the vitality and fluorescence required to make them indistinguishable from natural dentition. With increased brightness, higher shade consistency, natural opalescence and a wide range of characterization options this glass-ceramic material enables professional creativity when addressing a variety of restorative cases. Additionally, the IPS d.SIGN porcelain enables dentists to limit the majority of the veneer preparation to enamel, thereby reducing the risk of overexposing dentin.

Clinical preparation

After the patient had accepted the treatment plan, the dental technician created a diagnostic wax-up. In order to observe the principles of conservative preparation, a purely additive technique was used. Wax was added to the model to build up the new tooth forms.

A resin matrix (mock-up) then was created from the diagnostic wax-up to allow the patient to preview the restorations prior to tooth preparation. After patient approval, the mock-up was used as a blueprint for enamel reduction. The patient was anesthetized and depth cuts were placed in the incisal and cervical third of the matrix. Proper depth cuts were made with a diamond bur, using the matrix as a guide. The cuts were marked with a pencil for easy identification. The mock-up was removed and the necessary dental enamel for the veneer preparations was removed using large round-ended diamonds (Fig 2). Finally, the preparations were checked with vertical and palatal putty stents. These stents had been previously created from the diagnostic wax-up to ensure that the preparation is compatible with the veneer shape. The provisional restorations were inserted and checked. Particular emphasis was given to the embrasure form, where a space was left to allow the gingival tissue to fully recover after placement. The provisionals were spot-etched with phosphoric acid solution and luted with resin cement. The patient returned after a few days, a facebow was created, and the case was sent to the dental ceramist (Fig 3).

Laboratory procedure

The veneers were built up on the refractory dies using the IPS d.SIGN porcelain (Fig 4). Prior to the actual layering procedure, margin material was applied in a thin layer as far as the margins and baked. Porcelain stratification was initiated by placing a deep dentin on the facial, interproximal and incisal areas. For the subsequent layering steps, the resin matrix from the wax-up served as a guide. The veneers were then built up using dentin layers of different values and translucencies with the appropriate dentin materials and manual skills (Figs 5 and 6).

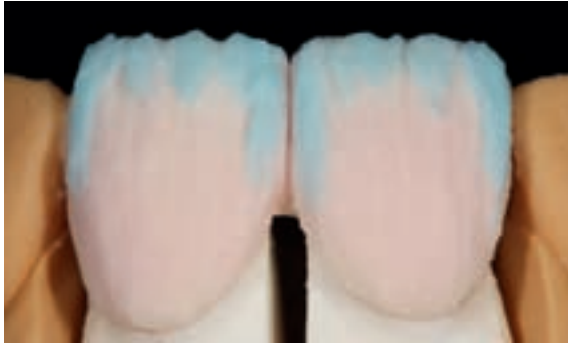

Fig 6 The stratification is created by applying various brightness and translucency levels.

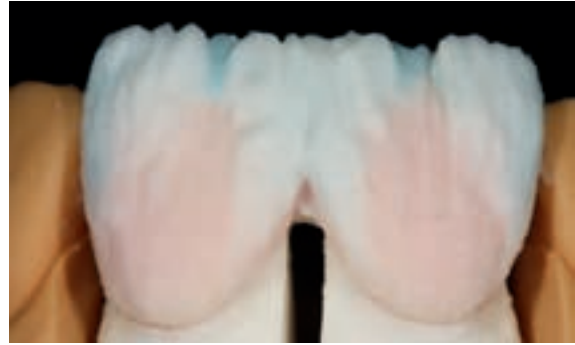


Fig 7 The dental lobes were created in the incisal area with some custom-mixed ivory- and cream-coloured materials, which were applied in thin layers.

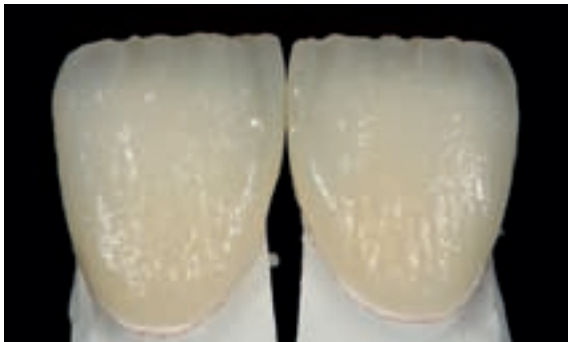

Fig 8 The baked veneers

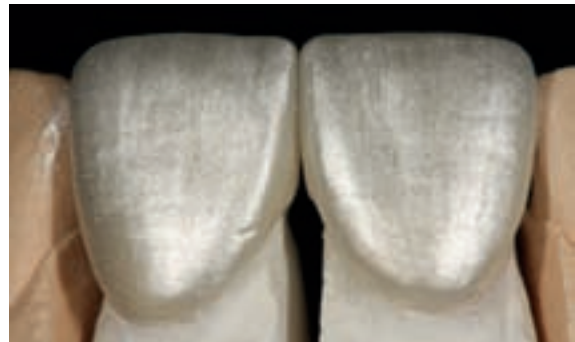

Fig 9 The entire porcelain surface was coated with silver powder to better assess symmetry and surface morphology.

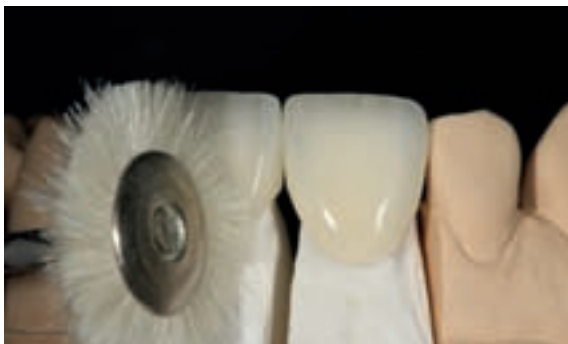

Fig 10 After thermal glazing, the restorations were mechanically polished.

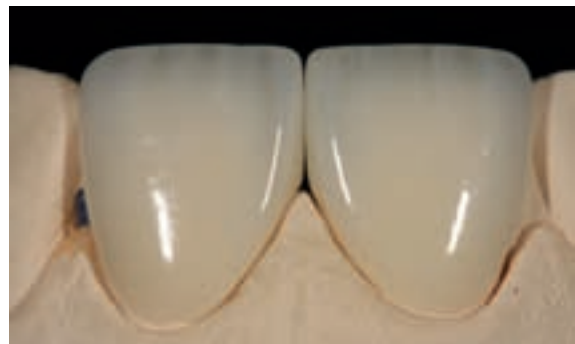

Fig 11 The delicate ceramic veneers already looked impressive on the model.

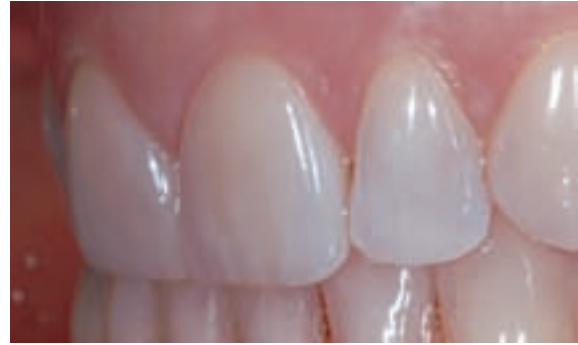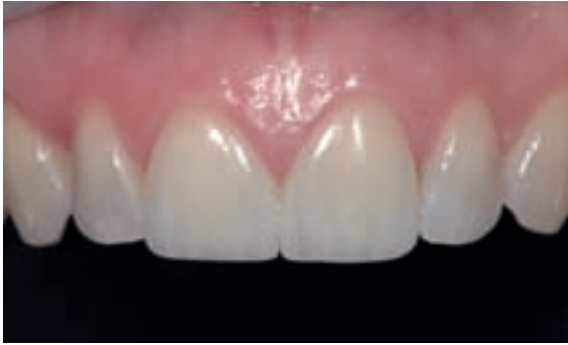Finally, the dental lobes were characterized by applying thin layers of custom-mixed ivory- and cream-coloured intensive materials (Fig 7). A combination of translucent and opalescent enamel powders was used to cover the entire facial aspect of the veneers (Fig 8). After the initial bake, the veneers were checked on the master dies. The contours and shape were finalized and the veneers were baked for a second time (Fig 9).

Final contouring and surface texturing was completed with diamond burs and green stones (Fig 10). After the final polish, the internal aspects of the veneers were etched with 9.5% hydrofluoric acid for 60 seconds.

The thin veneers were then ready for seating and delivered to the dentist (Fig 11).

Final seating

Once the provisionals had been removed, it was important to polish the preparations with pumice and to thoroughly clean them subsequently. The veneers were tried in individually to inspect the fit and then collectively to optimally evaluate the contact areas. The veneers were placed using a try-in gel in order to give the patient a preview of the final outcome. The result was outstanding, and thus the veneers were definitively luted into place according to standard bonding



Figs 12 and 13 The seated restorations

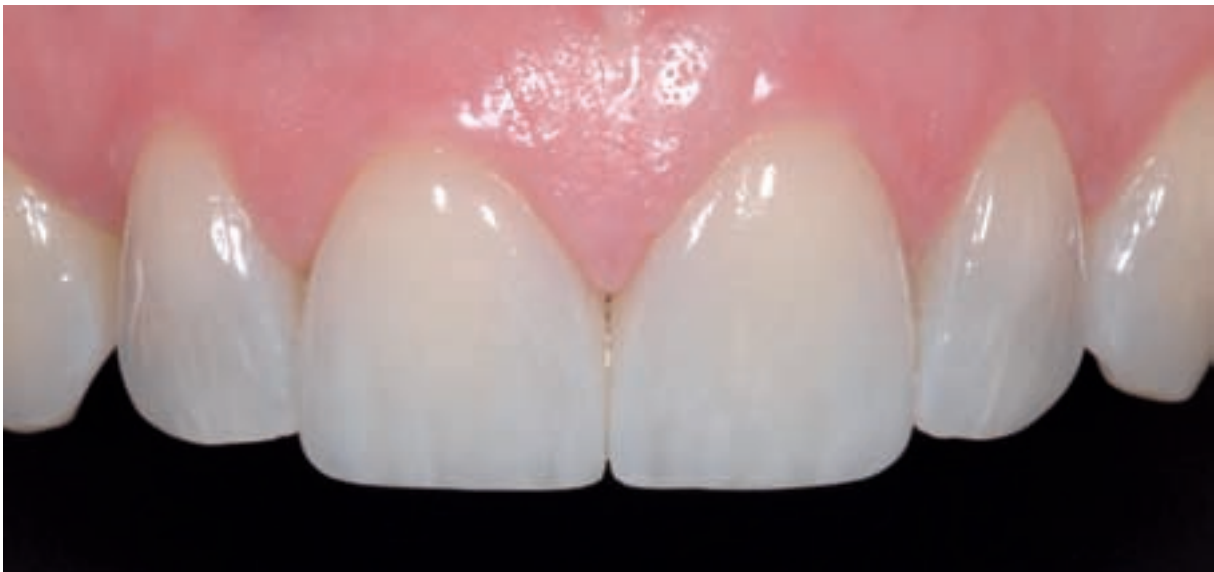

Fig 14 Two years after treatment: The gingiva is healthy and the patient still happy.

protocol with a resin cement. After final polishing, the occlusion was adjusted and checked. The patient's expectations had been met: The restorations closed the diastema. The newly designed anterior teeth fulfilled the esthetic expectations of the patient. Her smile was more relaxed and she looked more confident (Figs 12 and 13).

Conclusion

Bonded veneers can represent a minimally invasive treatment option. If the appearance of the anterior teeth is to be improved or modified, they are an attractive alternative to orthodontic treatment. The IPS d.SIGN fluorapatite material features properties which come very close to the optical and physical characteristics as well as the wear resistance of natural teeth. With this material, veneers can be fabricated which are virtually indistinguishable from natural dentition. The procedure discussed in this case allowed a con-

servative and highly esthetic veneer restoration to be fabricated. Both the patient's esthetic goals and the dentist's functional requirements were met (Fig 14). □

Contact details:

Dr Stephen Phelan
1500 Heritage Way
Oakville, Ontario
Canada
dr.sphelan@cogeco.ca



Harald Heindl, MDT
Aesthetic Dental Creations
Mill Creek, WA, 98012
USA
aedecr@comcast.net



On target with more brightness

Creating esthetic veneers with IPS e.max® Press

Benjamin Votteler, MDT, Pfullingen/Germany

The loss of tooth structure may have many causes, such as caries, abrasion or even dental trauma. Restoring the resulting dental defect by means of an adhesively luted ceramic restoration normally offers the best possible solution. Various methods are used to achieve this goal, such as layering over refractory dies and CAD/CAM applications. The press technique (hot pressing) presents an additional option and this method is discussed in detail in this report.

The press technique provides an ideal solution for creating veneers: high quality (shade, accuracy) can be achieved using an efficient working method. Whether or not a restoration seamlessly blends into the natural oral environment depends not only on the layering scheme applied by the dental technician. The press ceramic used to create the restoration also has an essential effect on the final outcome. The new IPS e.max® Press Impulse kit features new press ingots, which enable dental technicians to attain impressive results.

A 19-year-old female patient presented with a horizontal fracture in the incisal region with enamel splitting, which extended far into the palatal zone. This injury happened when the patient was 14 years old and fell onto the edge of a chair whilst playing.

However, there was good fortune in bad fortune: the two damaged anterior teeth remained vital. The teeth had been restored with temporary composite restorations to bridge the time until the patient reached the end of her growth phase. Now, it was time to provide her with a permanent restoration (Fig 1). As the shade of the anterior teeth was slightly brighter than the A1 shade in the dentin, or the dentin body, selecting appropriate press ingots was no easy task.

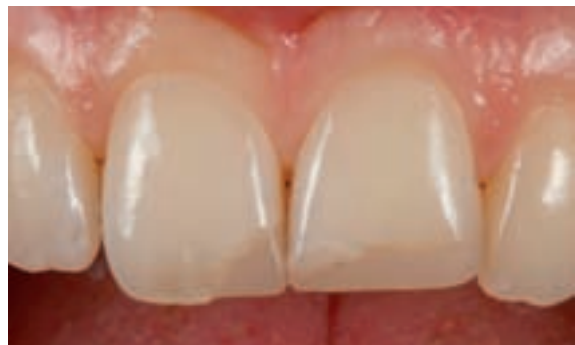

Fig 1 Initial situation: horizontal fracture with enamel splitting

In search of the correct material

Normally, I select an ingot that is one colour tone lighter than the actual tooth shade. This was not possible here. The Bleach BL ingots of the IPS e.max® Press LT (Low Translucency) range did not match the requirements of this case. In addition, the saturation of the Bleach ingot is too high to be suitable for veneers on non-discoloured tooth preparations and prevents the natural colour of the remaining tooth structure to shine through the restoration. Even the excellent light-optical properties of the IPS e.max Press® HT (High Translucency) press ingots were not suitable for this patient case.

As luck would have it, however, I attended an in-house continuing education course on all-ceramics held for opinion leaders at Ivoclar Vivadent just a few days before and there I received the first press ingots from the IPS e.max Press Impulse kit and was also able to see these materials in situ in the oral cavity of a patient. The Impulse ingots are available in three Value shades with different degrees of brightness and in two Opal shades with different levels of opacity.

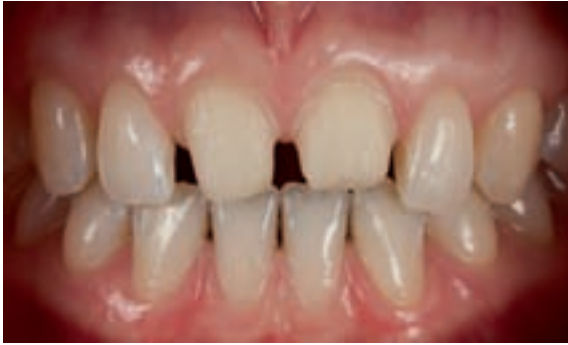

Fig 2 Conservative preparation design for 360° veneers

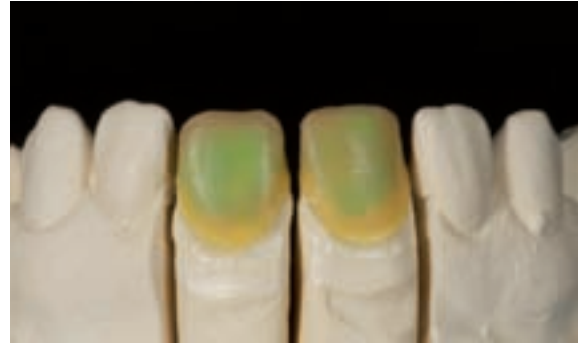


Fig 3 The IPS e.max Press Impulse copings modelled in wax



Fig 4 Copings after pressing of the ingots

I decided to use an individual layering technique for this patient case. The new Value ingots appeared to be the perfect material for this purpose. The translucency of these ingots is between that of the IPS e.max Press HT and the IPS e.max Press LT ingots. In addition, they offer a natural fluorescence. The chroma gradation is divided into three degrees (V1, V2, V3).

The following information was essential to produce the restoration: the shade of Value 1 is between HT BL1 and HT BL2 and the shades of Value 2 and Value 3 are between LT A1 and HT BL1. From my viewpoint, these ingots perfectly fill the gap in the range of ingots, providing the levels of brightness that hitherto have been missing. The opalescent characteristics of

the ingots are comparable to those of the IPS e.max Press HT materials.

Conservative tooth preparation was carried out on both the labial and palatal side to place 360° veneers (Fig 2). After an impression had been taken and a model created, the frameworks were designed in wax featuring a thickness of 0.4 to 0.5 mm (Fig 3) and pressed with the IPS e.max Press Impulse ingots in Value 1 (Fig 4). The press temperature of the ingots corresponds to that of the HT ingots. The reaction layer is almost entirely removed when the restoration is divested using glass beads (50 µm) at 2 bar pressure. In my opinion, using an appropriate furnace has a major effect on the outcome – for instance, the Programat® EP 5000 ensures gentle treatment of the material during the press cycle.

Structured layering

After foundation firing, the cervical and proximal areas were characterized with IPS e.max® Ceram stains (Shades and Essences) (Fig 5). The dentin body was built up. Transpa Neutral (TN) was applied in the incisal area to reduce the degree of saturation. Opal Effect 1 (OE 1) was applied to the proximal and incisal areas to mimic the youthful opalescent effects (Fig 6).

The structure of the mamelons caught my eye already during the shade selection process. A mixture of IPS

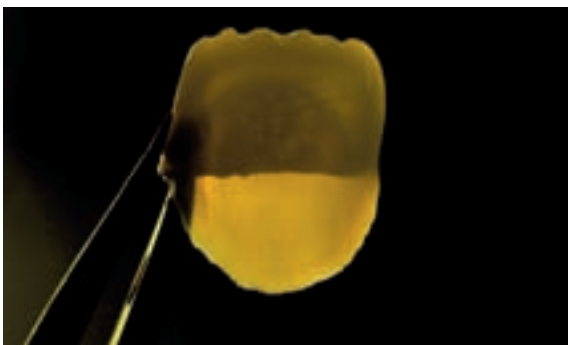


Fig 5 The frameworks show a lifelike opalescence.

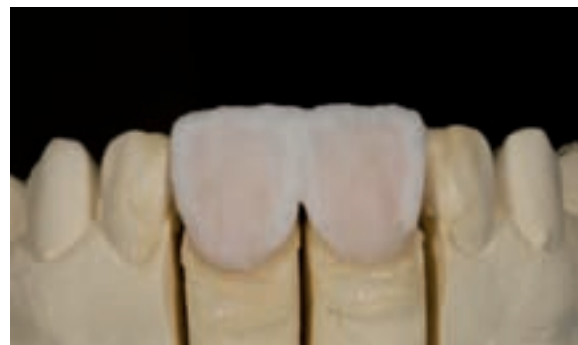

Fig 6 The youthful opalescent properties of the natural teeth can be mimicked in the proximal and incisal areas with Effect materials.



Fig 7 Reconstruction of the mamelons

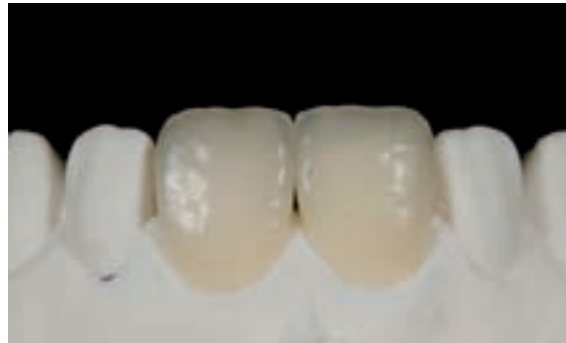

Fig 8 Layered veneers on the model

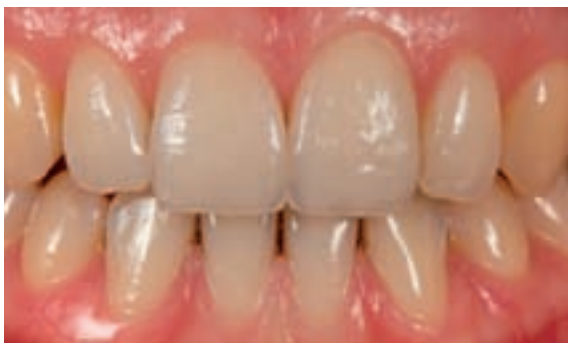

Fig 9 Try-in in the patient's mouth

e.max Ceram Mamelon materials enabled a lifelike reproduction of the mamelon. A soft transition between the internal structures and the body was achieved with Dentin/OE3 and the brightness value was adjusted. Various Enamel and Opal materials were used to complete the tooth shape on the labial side. To finish off the layering procedure for the main firing cycle, the restoration was framed with a layer of dentin to create a halo. The veneer was slightly overcontoured to compensate for material shrinkage. As a result, correction firing was obsolete (Fig 7).

As this was the first time I used the new Value ingots for a patient case, I was keen to check the esthetic effect in the patient's mouth (Fig 8). The image of the try-in clearly shows that a balanced translucent effect has been achieved in the restoration: no greying and no inappropriately intense masking of the substrate (Fig 9) can be seen.

High precision finishing

Finishing the form and functional aspects of the restoration is an essential part of my work. The surface was given its final structure with rotary instruments before glaze firing was conducted – gold powder is of particular use in this respect (Fig 10). After glaze firing, the proximal contacts and the occlusion were checked on the uncut model. To complete the procedure in the dental laboratory, the restoration was manually polished on a polishing unit using a fine pumice/Sidol mixture and a water soaked felt wheel (Fig 11).

Incorporating the restoration – a moment of suspense

The enamel surface of the prepared teeth were etched with 37% orthophosphoric acid for thirty seconds and then rinsed with a water/air spray for sixty seconds. The three-component bonding agent (Syntac® Classic) was applied according to the manufacturer's directions for use. At the same time, the all-ceramic restorations were etched with 9% hydrofluoric acid and after twenty seconds carefully rinsed with water.

Next, the restorations were cleaned with alcohol and subsequently silanated with Monobond Plus. Note: the restorations should be protected from light after application of the bonding agent (Heliobond® in this case). To prevent the conditioned surfaces from becoming contaminated, they should be etched and silanated not in the dental laboratory but immediately before they are placed in the oral cavity in the dental practice.

A purely light-curing luting composite (Variolink® Veneer), which is available in various degrees of brightness, is well suited for the cementation of these veneers. As an advantage, light-curing composites give users ample time to remove excess material.

After the 360° veneers were conditioned and filled with luting material, they were accurately placed on the tooth preparations and excess material was removed. Dental floss was used to remove surplus material from the interdental spaces, a brush for the margins and a small foam sponge for the palatal areas. Next, the veneers were polymerized to the tooth structure from the palatal and vestibular side for five seconds each side.

The operator applied Liquid Strip to the cement joints to prevent contact with oxygen (oxygen inhibition layer). If this precaution is not taken, there is a risk that the cement joints may discolour after a fairly short time.

Finally, the restorations were polymerized for sixty seconds from each side and the retraction cords were re-

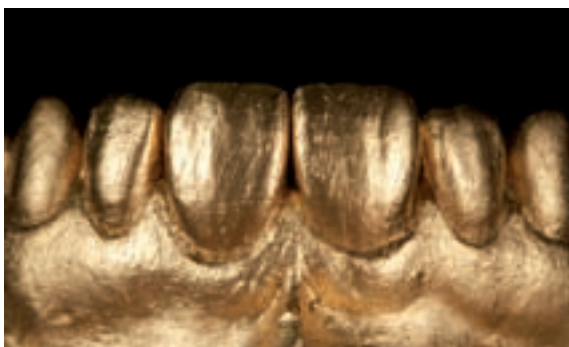

Fig 10 Gold powder facilitates the final contouring and shaping of the restorations.

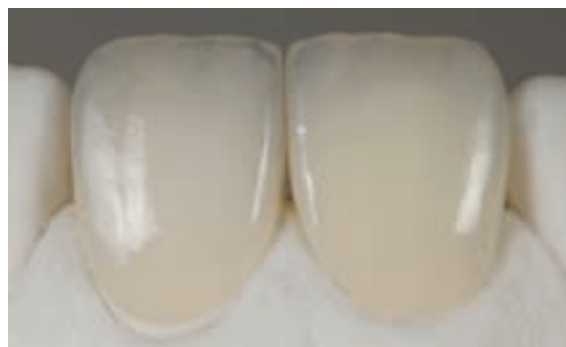

Fig 11 Completed veneers on the model

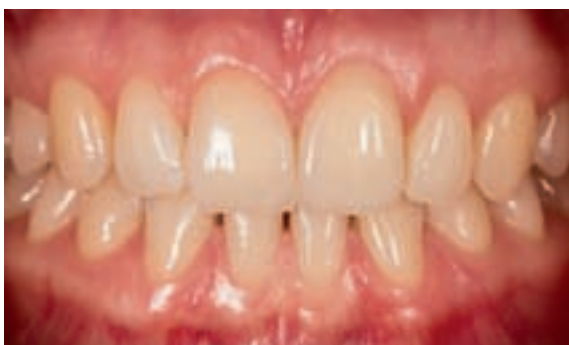

Fig 12 The restorations in situ optimally blend into the natural dentition.

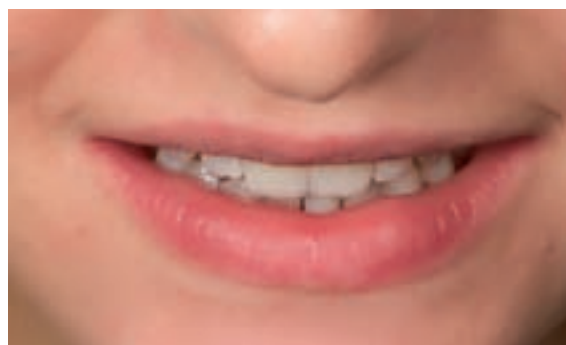


Fig 13 The result: harmonious contours of the lips ...

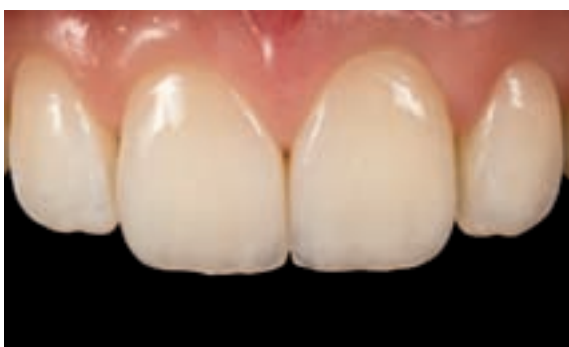

Fig 14 ... veneers with lifelike opalescent and ideal brightness effects and ...



Fig 15 ... ultimately a happy patient.

moved. Checking the sulci for remaining composite luting material is essential at this point. After the static and dynamic occlusion had been inspected, the treatment was completed (Figs 12 to 15).

Conclusion

The new IPS e.max Press Impulse Value ingots feature a translucency that lies between that of the IPS e.max Press HT and IPS e.max Press LT ingots. The fluorescent and opalescent properties of the press material optimally enhance the esthetics of the restoration. Like all the other materials from the IPS e.max Press range, these ingots offer a typical flexural strength of 400 MPa and therefore give the required peace of mind to the treatment team. □

Contact details:

Benjamin Votteler, MDT
Dentaltechnik Votteler GmbH & Co. KG
Arbach ob der Straße 10
72793 Pfullingen
Germany
benni@votteler.eu
www.votteler.eu



A lasting bond

Implant-borne single-tooth restorations using IPS e.max® CAD-on

Oliver Morhofer, MDT, and Bernd Kobus, MDT, Recklinghausen/Germany

Restoring complex patient cases in such a way that all restored teeth exhibit an identical shade even if they are restored with different framework materials requires an optimal selection of materials and adequate technical skills. Master dental technician Oliver Morhofer has had good experiences with the IPS e.max® range of materials and presents a case report on the fabrication of an implant-borne posterior restoration in conjunction with the IPS e.max CAD-on technique.

Achieving a natural esthetic appearance in a restoration plays an important role for patients. Increasing numbers of patients request all-ceramic treatment options and so did the female patient whose case is presented below. The objective of her treatment was to restore teeth 44 and 47 with single crowns and to prosthetically restore the implants in region 45 and 46 (Frialit® 2, Dentsply Friadent) (Fig 1). Although not planned initially, tooth 43 was also included in the treatment because of cosmetic considerations. For this purpose, the existing metal core build-up needed to be reduced (Fig 2). With regard to shade selection, we decided to opt for A2 as the basic shade. Temporization was achieved with a temporary bridge made of

Telio® CAD. This temporary material is available in industrially manufactured high-density polymer blocks, which can be utilized to fabricate temporary crowns and bridges in a relatively straightforward fashion using CAD/CAM technology. The resulting temporaries may remain in the oral cavity for up to twelve months and feature excellent physical properties. As they are industrially polymerized to a completely hardened state they do not irritate the mucous membrane and offer a high degree of biocompatibility. The dense surfaces ensure that the restorations have a considerably more pleasant feel than many other traditional temporary materials when touched by the tongue. Moreover, temporary restorations made of Telio CAD can be characterized if required.

Finally being able to chew properly again

For the present case, the temporary restoration was milled with an inLab system (Sirona). After milling, the attachment points were removed using separating discs. The temporary was fitted to the model and the crown margins, interdental spaces, occlusal surfaces and the marginal edge portions of surfaces were smoothed out using a handpiece and silicone polishing wheel. Subsequently, the restoration was polished to a

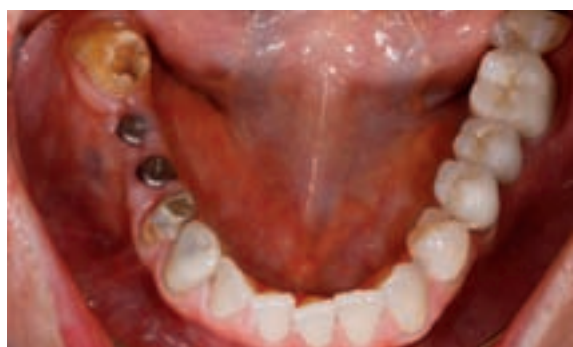
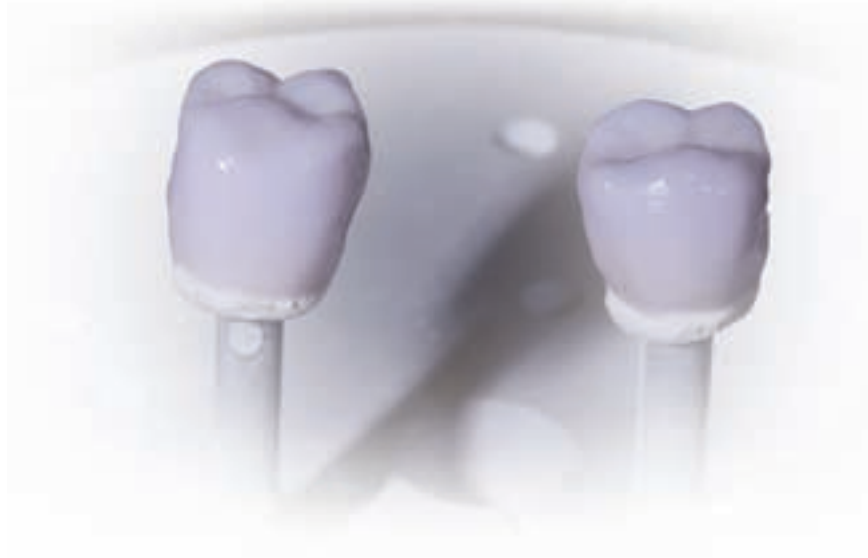
Fig 1 Teeth 44 and 47 were prepared to be restored with crowns. The post and core build-up was left in place.

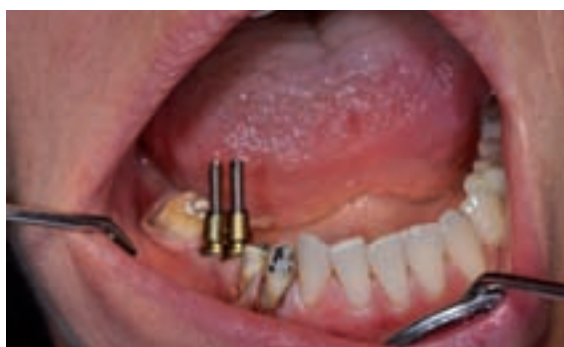

Fig 2 Although not planned initially, tooth 43 was also included in the treatment and the existing metal build-up was reduced.

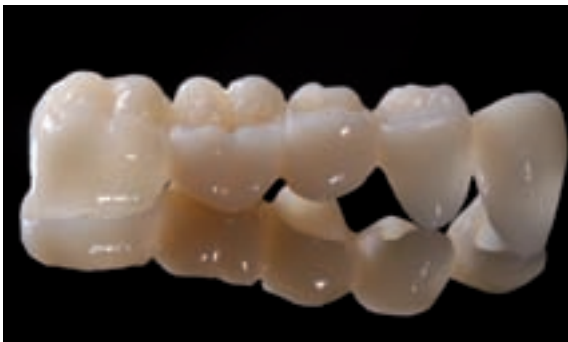

Fig 3 The temporary restoration was milled from Telio CAD blocks.

high gloss with a goat's hair brush, cotton buff and polishing paste using low rpm and gentle pressure.

In our experience, patients look forward to their final restorations with even greater anticipation if the temporary is optically and functionally well designed. We are more than happy to take advantage of the esthetic possibilities offered by the light-curing composite and characterization materials of the Telio® range to accommodate the requests of our patients, particularly when fabricating anterior restorations. In this case, however, we refrained from using stains or composites to characterize the restoration as the temporary was supposed to stay in the oral cavity for only a short time (Fig 3). As the metal build-ups on tooth 43 and 44 would have severely impaired the esthetic appearance of the light-transmitting restorations, the clinician masked them with tooth-coloured composite material (Fig 4). Together, we therefore achieved a pleasing temporary restoration with which the patient was completely satisfied for the entire length of the temporization even if we did not apply any characterizations. She was happy that she was finally able to chew properly again due to the "newly" designed occlusion (Fig 5).

A wealth of possibilities

The patient felt comfortable with the temporary restoration and we therefore had plenty of time to design and create the final restoration in the lab. The innovative CAD-on technology of the IPS e.max range was utilized for this purpose. This new technique allows veneering structures made of the highly esthetic lithium disilicate glass-ceramic (LS₂) IPS e.max® CAD to be fused to high-strength IPS e.max® ZirCAD zirconium oxide frameworks (ZrO₂) by means of a newly designed fusion glass-ceramic (IPS e.max® CAD Crystall./Connect). High-strength CAD-on restorations are suitable for posterior bridges that may include up to four units. As the opaque zirconium oxide frameworks prevent the metal abutments from shining through the restorative material, IPS e.max CAD-on is also suitable for implant-borne restorations. The framework and

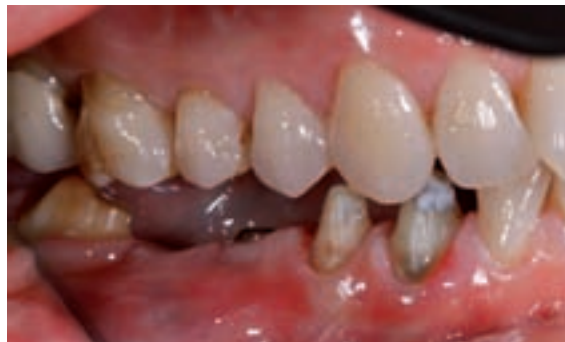

Fig 4 The metal build-ups needed to be masked with tooth-coloured composite material.

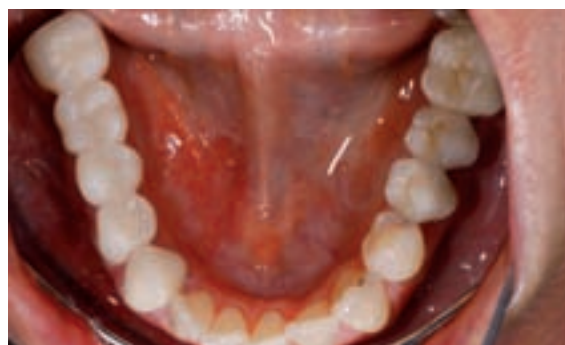

Fig 5 The patient was pleased with the fact that the temporary restoration helped her to regain her normal occlusal functions.

veneering structure are designed using software tools and then milled consecutively in the same milling unit. After the zirconium oxide framework has been sintered, both components are fused together using the IPS e.max CAD Crystall./Connect fusion glass-ceramic. This method provides superior esthetic results combined with exceptional strength and durability.

The advantage of having options

For the case presented here, the prepared natural teeth and implants had to be restored individually. We took advantage of the large variety of IPS e.max materials to achieve the most esthetic and durable result that we could. Since the shade of the preparation has an effect on an all-ceramic restoration, it is essential to inform the dental technician of the exact preparation shade. Accurate colour communication between clinician and technician is also indispensable to select the correct tooth shade and, consequently, the right material. To cover the core build-up on tooth 44 and the two implants, we designed zirconium oxide copings using the inLab software and milled them from IPS e.max ZirCAD blocks in shade MO 1. The Multilayer design software enabled us to design the CAD-on veneering structures for teeth 45 and 46 in the course of the same digital construction step. We milled the LS₂ veneering structures in shade HT A2 (high translucency) according to the manufacturer's recommendations (Fig 6). The ZrO₂ frameworks were dried prior to

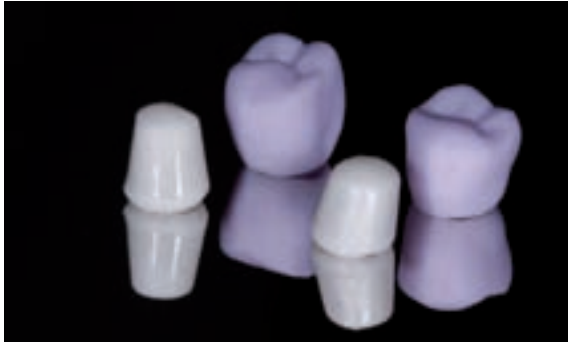

Fig 6 The abutments received IPS e.max CAD-on restorations.

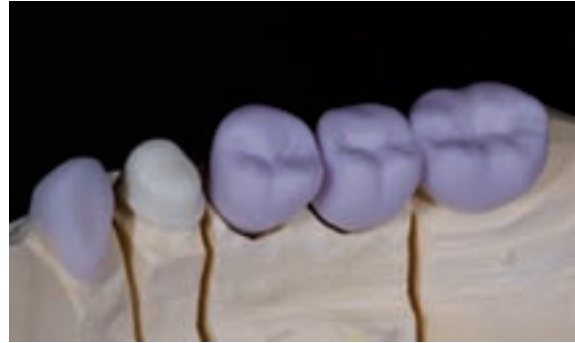

Fig 7 Whilst unsintered, the veneering structures were fitted onto the model and slightly adjusted.

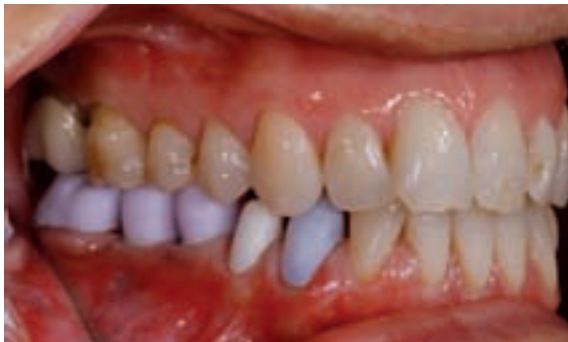

Fig 8 The occlusal fit should be checked in any case before the components are fused together.

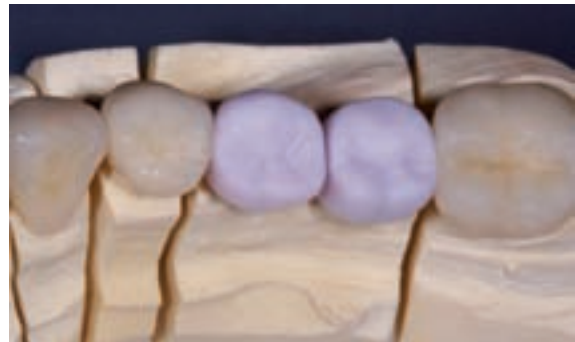

Fig 9 The crowns for teeth 43 and 44 were created using an individual layering technique. Only then did we fuse and crystallize the crowns for teeth 45 and 46.

further processing, sintered in a Programat® S1 furnace and their accuracy of fit checked on the model. We generally prefer to use an individual ceramic layering technique for restorations in the visible region. Therefore, we milled a coping from IPS e.max CAD in shade MO (medium opacity) to create a substructure for tooth 43. The restoration of tooth 47 was designed as a full-contour crown made of IPS e.max CAD in LT A2 (low translucency). This selection of choices is representative of the extensive range of IPS e.max materials and the IPS e.max opacity and translucency scheme. The manifold combination possibilities allow users to find an ideal treatment option for virtually all indications in the dental laboratory using zirconium oxide ceramics and lithium disilicate glass-ceramics together.

High degree of reliability

The edges of the milled frameworks were carefully reworked using a silicone polisher. In accordance with the recommendations of Ivoclar Vivadent, the veneering structures were tried in on the model in such a way that they only rested on the cervical shoulder of the ZirCAD framework. Next, we slightly smoothed the occlusal surface using fine diamonds and created a natural surface texture (Fig 7). Before the components were fused together, the restoration was tried in on the patient to ensure that the bite conditions transferred by the temporary complied with the envisaged final occlusion (Fig 8).

The full-contour IPS e.max CAD crown for tooth 47 was crystallized in a Programat® P500 ceramic furnace applying two holding stages. The veneers for the frameworks for teeth 43 and 44 were individually layered with IPS e.max® Ceram (Fig 9). Subsequently, we fused the CAD-on veneering structures for tooth 45 and the premolarized tooth 46.

The purpose-designed IPS e.max CAD Crystall./Connect fusion ceramic is available in nine shades. This selection allows an accurate reproduction of the desired tooth shade. We used an MO 1 zirconium oxide block for the framework and shade HT A2 for the lithium disilicate veneering structure to achieve tooth shade A2, as required for this patient case. This combination was derived from the materials combination table. Veneering structures undergo fusion and crystallization in a single firing cycle when the CAD-on technique is used. For this process, a small amount of Connect material was applied into the veneer using an IPS Spatula and distributed to form a homogeneous layer on an Ivomix vibrator (Fig 10). Next, the framework was placed onto the veneer in its exact position and the two components were homogeneously integrated with each other using light pressure. Connect material was now seeping from the margins of the restoration. This material is only liquid when exposed to vibration and turns into a solid state as soon as the vibration stops. Consequently, the joined restoration can be placed in the articulator to evaluate its occlusal fit before it is fired.

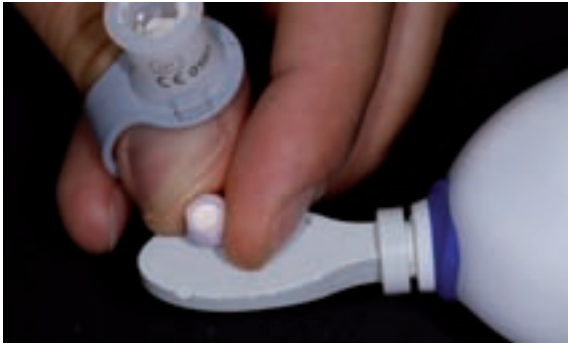

Fig 10 The framework and veneering structure were joined together with IPS e.max CAD Crystall./Connect material.

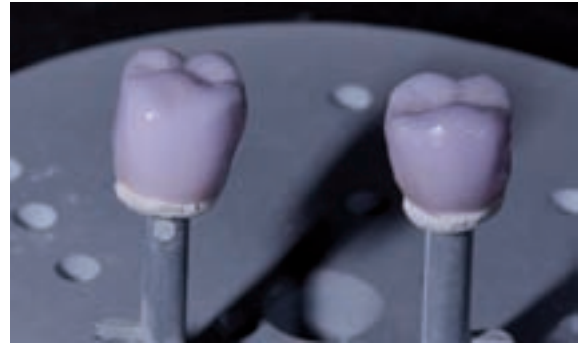

Fig 11 We applied a few shade characterizations to the "blue" restoration even before fusion firing.

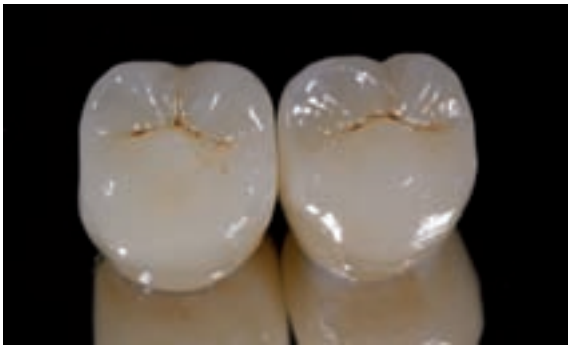

Fig 12 The combination of IPS e.max ZirCAD ZrO₂ and IPS e.max CAD LS₂ results in high-strength esthetic restorations.

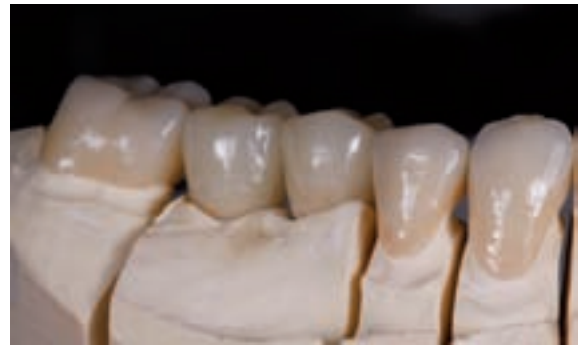

Fig 13 A safe bet – restorations made of IPS e.max CAD-on minimize the risk of fracture and create a vibrant lifelike appearance.

A larger selection, a better result

As the fusion process and crystallization are conducted simultaneously and the "blue" restoration is characterized in the process, shade characterizations are always applied using IPS e.max CAD Crystall./Shades and Stains (Fig 11). After having undergone firing at 840 °C, the two components are permanently fused together in a homogeneous bond. An additional firing was conducted to customize the occlusal surfaces of the crowns with Add-on Incisal and Add-on Dentin materials. After glaze firing, the restorations showed a vibrant, true-to-nature appearance (Fig 12). Even from a vestibular view, the shade characteristics of the crowns are seamlessly coordinated with one another in spite of the fact that several materials, different degrees of translucency and substructures have been used in the restorations. The homogeneous quality of the surface was also impressive (Fig 13). Thus, this method allowed us to create high-strength restorations that minimize the risk of fracture. They are particularly useful for use in conjunction with implants, if an appropriate emergence profile cannot be attained in the mandible because only a limited amount of bone support is available. These materials are a joy to work with and give pleasure to the patient, dentist and dental technician alike (Fig 14).

Acknowledgement

We would like to thank Dr Baris Yanik, Dr Dr Thomas Olivier and Dr Tobias Wienhöfer in Recklinghausen for their excellent cooperation and preparation. □

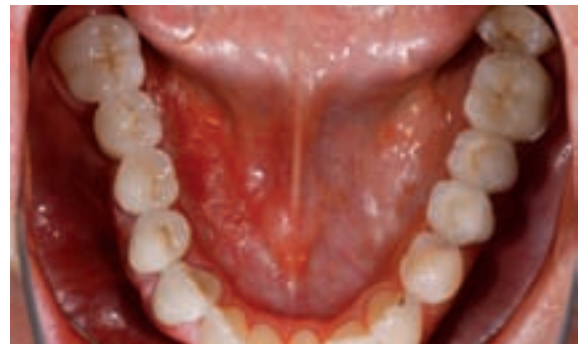

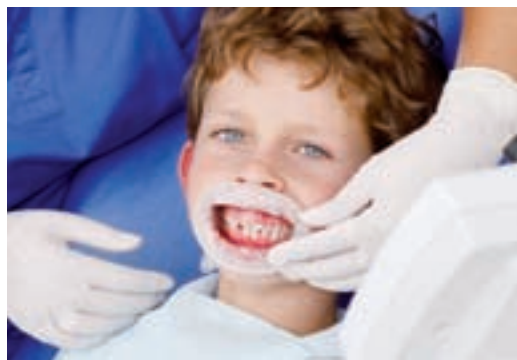Fig 14 Simply beautiful – the shade characteristics of the restorations are completely coordinated with each other even if different materials are used.

Contact details:

Oliver Morhofer, MDT
High-Tech-Dental GmbH
Große Geldstraße 18
45657 Recklinghausen
Germany
o.morhofer@high-tech-dental.de
www.high-tech-dental.de

Bernd Kobus, MDT
High-Tech-Dental GmbH
Große Geldstraße 18
45657 Recklinghausen
Germany
b.kobus@high-tech-dental.de
www.high-tech-dental.de





Distinguished by innovation

Healthy teeth produce a radiant smile. We strive to achieve this goal on a daily basis. It inspires us to search for innovative, economic and esthetic solutions for direct filling procedures and the fabrication of indirect, fixed or removable restorations, so that you have quality products at your disposal to help people regain a beautiful smile.

www.ivoclarvivadent.com

Ivoclar Vivadent AG

638371 Bendererstr. 2 | FL-9494 Schaan | Liechtenstein | Tel.: +423 / 235 35 35 | Fax: +423 / 235 33 60


ivoclar
vivadent®
passion vision innovation